

ISSN 2518-1483 (Online),
ISSN 2224-5227 (Print)

2020 • 4

ҚАЗАҚСТАН РЕСПУБЛИКАСЫ
ҰЛТТЫҚ ҒЫЛЫМ АКАДЕМИЯСЫНЫҢ

БАЯНДАМАЛАРЫ

ДОКЛАДЫ

НАЦИОНАЛЬНОЙ АКАДЕМИИ НАУК
РЕСПУБЛИКИ КАЗАХСТАН

REPORTS

OF THE NATIONAL ACADEMY OF SCIENCES
OF THE REPUBLIC OF KAZAKHSTAN

PUBLISHED SINCE 1944



ALMATY, NAS RK

Бас редакторы
х.ғ.д., проф., ҚР ҰҒА академигі
М.Ж. Жұрынов

Редакция алқасы:

Адекенов С.М. проф., академик (Қазақстан) (бас ред. орынбасары)
Бенберин В.В., проф., академик (Қазақстан)
Березин В.Э., проф., корр.-мүшесі (Қазақстан)
Величкин В.И. проф., корр.-мүшесі (Ресей)
Вольдемар Вуйцик проф. (Польша)
Елешев Р.Е., проф., академик (Қазақстан)
Жамбакин Қ.Ж., проф., академик (Қазақстан)
Иванов Н.П., проф., академик (Қазақстан)
Илолов М.И. проф., академик (Тәжікстан)
Кригер Виктор проф. (Германия)
Кененбаев С.Б., проф., академик (Қазақстан)
Леска Богуслава проф. (Польша)
Локшин В.Н. проф., академик (Қазақстан)
Неклюдов И.М. проф., академик (Украина)
Нур Изура Удзир проф. (Малайзия)
Нургожин Т.С., проф., корр.-мүшесі (Қазақстан)
Перни Стефано проф. (Ұлыбритания)
Потапов В.А. проф. (Украина)
Прокопович Полина проф. (Ұлыбритания)
Рамазанов Т.С. проф., академик (Қазақстан)
Раманкулов Е.М., проф., корр.-мүшесі (Қазақстан)
Садықұлов Т., проф., академик (Қазақстан)
Семенова В.Г., проф., академик (Россия)
Сикорски Марек проф., (Польша)
Такибаев Н.Ж. проф., академик (Қазақстан), бас ред. орынбасары
Уразалиев Р.А., проф., академик (Қазақстан)
Харин С.Н. проф., академик (Қазақстан)
Харун Парлар проф. (Германия)
Чечин Л.М. проф., корр.-мүшесі (Қазақстан)
Энджун Гао проф. (Қытай)

«Қазақстан Республикасы Ұлттық ғылым академиясының баяндамалары»

ISSN 2518-1483 (Online),

ISSN 2224-5227 (Print)

Меншіктенуші: «Қазақстан Республикасының Ұлттық ғылым академиясы» Республикалық қоғамдық бірлестігі (Алматы қ.).
Қазақстан Республикасының Ақпарат және қоғамдық даму министрлігінің Ақпарат комитетінде 29.07.2020 ж. берілген
№ KZ93VPY00025418 мерзімдік басылым тіркеуіне қойылу туралы куәлік.

Мерзімділігі: жылына 6 рет.

Тиражы: 500 дана.

Редакцияның мекенжайы: 050010, Алматы қ., Шевченко көш., 28; 219, 220 бөл.; тел.: 272-13-19, 272-13-18,
<http://reports-science.kz/index.php/en/archive>

© Қазақстан Республикасының Ұлттық ғылым академиясы, 2020

Типографияның мекенжайы: «NuNaz GRACE», Алматы қ., Рысқұлов көш., 103.

Главный редактор
д.х.н., проф., академик НАН РК
М. Ж. Журинов

Редакционная коллегия:

Адекенов С.М. проф., академик (Казахстан) (зам. гл. ред.)
Бенберин В.В., проф., академик (Казахстан)
Березин В.Э., проф., чл.-корр. (Казахстан)
Величкин В.И. проф., чл.-корр. (Россия)
Вольдемар Вуйцик проф. (Польша)
Елешев Р.Е., проф., академик (Казахстан)
Жамбакин К.Ж., проф., академик (Казахстан)
Иванов Н.П., проф., академик (Казахстан)
Илолов М.И. проф., академик (Таджикистан)
Кригер Виктор проф. (Германия)
Кененбаев С.Б., проф., академик (Казахстан)
Леска Богуслава проф. (Польша)
Локшин В.Н. проф., академик (Казахстан)
Неклюдов И.М. проф., академик (Украина)
Нур Изура Удзир проф. (Малайзия)
Нургожин Т.С., проф., чл.-корр. (Казахстан)
Перни Стефано проф. (Великобритания)
Потапов В.А. проф. (Украина)
Прокопович Полина проф. (Великобритания)
Рамазанов Т.С. проф., академик (Казахстан)
Раманкулов Е.М., проф., чл.-корр. (Казахстан)
Садыкулов Т., проф., академик (Казахстан)
Семенова В.Г., проф., академик (Россия)
Сикорски Марек проф., (Польша)
Такибаев Н.Ж. проф., академик (Казахстан), зам. гл. ред.
Уразалиев Р.А., проф., академик (Казахстан)
Харин С.Н. проф., академик (Казахстан)
Харун Парлар проф. (Германия)
Чечин Л.М. проф., чл.-корр. (Казахстан)
Энджун Гао проф. (Китай)

Доклады Национальной академии наук Республики Казахстан»

ISSN 2518-1483 (Online),

ISSN 2224-5227 (Print)

Собственник: Республиканское общественное объединение «Национальная академия наук Республики Казахстан» (г. Алматы).

Свидетельство о постановке на учет периодического печатного издания в Комитете информации Министерства информации и общественного развития Республики Казахстан № **KZ93VPY00025418**, выданное 29.07.2020 г.

Периодичность: 6 раз в год.

Тираж: 500 экземпляров

Адрес редакции: 050010, г. Алматы, ул. Шевченко, 28; ком. 219, 220; тел. 272-13-19, 272-13-18,

<http://reports-science.kz/index.php/en/archive>

© Национальная академия наук Республики Казахстан, 2020 г.

Адрес типографии: «NurNaz GRACE», г. Алматы, ул. Рыскулова, 103.

E d i t o r i n c h i e f

doctor of chemistry, professor, academician of NAS RK

M.Zh. Zhurinov**E d i t o r i a l b o a r d:**

Adekenov S.M. prof., academician (Kazakhstan) (deputy editor in chief)
Benberin V.V., prof., academician (Kazakhstan)
Berezin V.Ye., prof., corr. member. (Kazakhstan)
Velichkin V.I. prof., corr. member (Russia)
Voitsik Valdemar prof. (Poland)
Eleshev R.E., prof., academician (Kazakhstan)
Zhambakin K.Zh., prof., academician (Kazakhstan)
Ivanov N.P., prof., academician (Kazakhstan)
Iolov M.I. prof., academician (Tadjikistan)
Krieger Viktor prof. (Germany)
Kenenbayev S.B., prof., academician (Kazakhstan)
Leska Boguslava prof. (Poland)
Lokshin V.N. prof., academician (Kazakhstan)
Neklyudov I.M. prof., academician (Ukraine)
Nur Izura Udzir prof. (Malaysia)
Nurgozhin T.S., prof., corr. member. (Kazakhstan)
Perni Stephano prof. (Great Britain)
Potapov V.A. prof. (Ukraine)
Prokopovich Polina prof. (Great Britain)
Ramankulov E.M., prof., corr. member. (Kazakhstan)
Sadykulov T., prof., academician (Kazakhstan)
Semenova V.G., prof., academician (Russia)
Sikorski Marek prof., (Poland)
Ramazanov T.S. prof., academician (Kazakhstan)
Takibayev N.Zh. prof., academician (Kazakhstan), deputy editor in chief
Urazaliyev R.A., prof., academician (Kazakhstan)
Kharin S.N. prof., academician (Kazakhstan)
Kharun Parlar prof. (Germany)
Chechin L.M. prof., corr. member (Kazakhstan)
Endzhun Gao prof. (China)

Reports of the National Academy of Sciences of the Republic of Kazakhstan.**ISSN 2224-5227****ISSN 2518-1483 (Online),****ISSN 2224-5227 (Print)**

Owner: RPA "National Academy of Sciences of the Republic of Kazakhstan" (Almaty).

The certificate of registration of a periodical printed publication in the Committee of information of the Ministry of Information and Social Development of the Republic of Kazakhstan **No. KZ93VPY00025418**, issued 29.07.2020.

Periodicity: 6 times a year.

Circulation: 500 copies.

Editorial address: 28, Shevchenko str., of. 219, 220, Almaty, 050010, tel. 272-13-19, 272-13-18,

<http://reports-science.kz/index.php/en/archive>

© National Academy of Sciences of the Republic of Kazakhstan, 2020

Address of printing house: «NurNaz GRACE», 103, Ryskulov str, Almaty.

S.N. Abdreshov¹, U.N. Kozhaniyazova¹,
G.A. Demchenko¹, Sh.S. Shynybekova², U.B. Nauryzbay¹

¹Institute of Human and Animal Physiology CS MES RK, Kazakhstan, Almaty

²Abai Kazakh National Pedagogical University, Kazakhstan, Almaty.

E-mail: SNABDRESHOV@mail.ru

FEATURES OF MORPHOFUNCTIONAL CONDITION OF THE THYROID GLAND AND REGIONAL LYMPH NODE IN NORMAL AND IN HYPOTHYROIDISM

Abstract. The article presents data on the ratio of the functional structures of the lymph nodes in thyroid failure. Taking mercazolilum within 30 days led to a disorder of the morphofunctional condition of the thyroid gland and cervical lymph node. According to histological and morphometric analysis of the thyroid gland, a high sensitivity to monthly exposure of mercazolilum is shown, which is expressed in a synchronous morphological rearrangement of the tissue microdistrict of the thyroid gland and lymph node. Changes were identified especially in the peripheral zones of the thyroid lobes, which led to a decrease in the size of follicles, and in thyrocytes to a change in cellular elements, which caused a decrease in the production of thyroid hormones and developmental disability of reactive and compensatory changes in the thyroid gland. The structurally functional component related to both the thyroid gland and the lymph node is the extracellular space with vascular and non-vascular paths of microcirculation, a change in which leads to disruption of the vesicular-colloid transport in the thyroid cytoplasm and to a change in the functional state of the thyroid gland.

There are changes in the regional lymph node, which are characterized by a change in the ratio of cortical and medullary substance, in which the proportion of structures of the cortical substance decreases; there was an increase in the number of macrophages in the lymphoid nodule, the medullar sinus, a decrease in the number of mature plasmocytes, in the paracortex and Billroth's stand. These changes indicate an immunosuppressive effect on the lymph node. On sections of the lymph node, capsule infiltration with lymphoid elements was often observed. The value of paracortex was statistically significantly reduced. The decrease in the area of the paracortical zone is relative, since it occurs due to the formation of sinuses. Blood vessels are blood-filled in the lymph node. There was an increase in the volume of the lymph node, which leads to a uniform development of the structures of the cortical and medullar substance of the lymph node.

Keywords: hypothyroidism, blood, rats, lymph node, thyroid gland.

Introduction. The prevalence of hypothyroidism is one of the first among all endocrine diseases, and its prevalence increases with age. The pathology of the thyroid gland is reflected in the provision of endocrine, immunological, energetic homeostasis of the body [1, 2]. It has been established that hypothyroidism develops disturbances in the mechanisms of oxidative homeostasis, and spontaneous luminosity in the liver decreases. Studies have shown that with hypothyroidism, the enzymatic activities of malate dehydrogenase, glutamate dehydrogenase, glucose-6-phosphate dehydrogenase, arginase and activation of succinate dehydrogenase are reduced [3, 4].

The lymphatic system is one of the main links in the chain of humoral blood-tissue-lymph-blood transport [5, 6, 7], and taking into account the important role of the lymphatic system in maintaining homeostasis in the body with thyroid insufficiency is relevant. It is known that lymph nodes play an

important role in the formation of humoral and cellular immunity [8, 9]. Among the most important and universal functions of the lymph nodes, regardless of their localization and organ affiliation, their hematopoietic and immunopoietic, protective and filtering roles in the body are especially distinguished [10, 11].

The role of the lymphatic system and its lymphoid organs is one of the little studied problems in biology, in the protective reactions of the body under the influence of negative environmental factors on the human body. Of interest is the study of the condition of the lymphatic system in hypothyroidism.

Lymph nodes play an important role in the life of humans and animals [12]. Lymph nodes are the main homeostatic organs of the internal environment of the body [13, 14]. Due to the fact that their structural and functional response to environmental influences has the features of general stereotype, the morphological and functional status of lymph nodes can be a marker of environmental pressure on the lymphatic system [15]. In the modern concept of the lymphatic region, to determine the condition of the organ drained by it, great prognostic significance is given to the structural and functional condition of the lymph node [16, 17].

Lymph nodes are organs of lymphopoiesis and peripheral organs of immunogenesis. The inflow lymphatic vessels, which carry lymph both directly from the organs and from other lymph nodes run into them. The efferent lymphatic vessels go out of the lymph nodes, heading to other nodes or to the trunks and ducts.

The thyroid gland is the only endocrine organ in which bi-directional movement of products intended for secretion into the blood occurs. The thyroid gland is a tissue microdistrict that combines a group of follicles with an autonomous system of blood and lymph circulation. The aim of this research was to study the morphological and functional features of the thyroid gland and regional lymph nodes in animals at hypothyroidism.

Material and methods of research. The experiments were performed on 35 white laboratory rats males weighing 250 ± 3 g. Experimental hypothyroidism in experimental rats was modeled according to the method of Orlov, 2002 [18, 19]. To develop the condition of experimental hypothyroidism, mercazolilum dissolved in water at a dose of 20 mg per 100 g of animal body weight was administered to rats of the experimental group daily for 30 days. Animals were divided into two groups. Rats of the 1st group (15 rats) were control. In rats of the 2nd group (20 rats), a condition of hypothyroidism was induced for 30 days. The duration of the experiment is 31 days. All groups of animals were in the same conditions of feeding and keeping. All experiments with animals were carried out in strict accordance with the rules developed and approved by the local ethical commission of KazNMU named after S.D. Asfendiyarov, as well as in accordance with the rules and requirements stipulated by the 1986 directive of the European Parliament and set out in the "Guide for the Care and Use of Laboratory Animals."

For histological examination, lymph nodes were taken from rats. They were then fixed in a 10% solution of neutral formalin, then the samples were washed with tap water and dehydrated in alcohol with increasing concentration and pouring material into paraffin, followed by preparation of histological sections 4–5 μm thick, obtained using a ThermoScientificHM 325 microtome. Histological sections of lymph nodes were stained with hematoxylin and eosin, azure and eosin [20]. Drugs were viewed under a Leica 1000 light microscope with a camera.

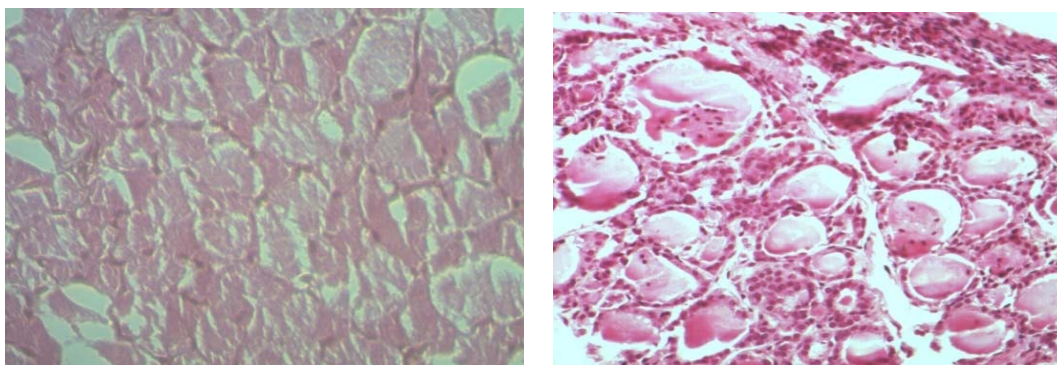
Morphometric analysis was carried out using a morphometric grid [21], which was superimposed on a section of the lymph node. The intersections of the network occurring across the entire section of the lymph node, as a whole and separately, for each of its structures — the capsule, cortical plateau, lymphoid nodules, paracortex, meat strands and sinuses, with recalculation in percent were calculated [22, 23]. During cytological analysis of the structure of lymph nodes and plaques, the number of cells in a standard area of 1600 μm^2 with their differentiation into blasts, medium and small lymphocytes, plasmocytes, macrophages, and others were calculated. For some structural and functional zones, reference values for cells were used.

The data obtained were subjected to statistical processing with determination of arithmetic mean (M), arithmetic mean error ($\pm m$) and significance of differences at $P < 0.05$ using the statistical analysis program StatPlus Pro 2009, AnalystSoft Inc

The results and their discussion. The work provides material on the study of the state of the thyroid gland and lymph nodes in control animals and groups after experimental hypothyroidism. Rats with hypothyroidism were distinguished by the presence of characteristic symptoms - low mobility, lack of

appetite, drowsiness, hair slip from the face surfaces of the body. The average mass of the thyroid gland of the rats of the control group is 0.014 ± 0.001 g. The mass of the left lobe is 0.008 ± 0.002 g, the right is 0.006 ± 0.004 g. The length of the left lobe is from 0.5 ± 0.014 to 0.7 ± 0.011 mm, the right lobe it is between 0.32 ± 0.007 and 0.34 ± 0.009 mm. The obtained digital data indicate the prevalence of the parameters of the left lobe over the right lobe of the thyroid gland in rats.

The control group of animals has a thyroid gland of elastic consistency, red in color with a reddish-brown and sometimes pink hue. The thyroid gland is of normal structure with the preservation of its basic structural elements. In this group, the thyroid gland contains rounded and oval follicles, in the cavity of which a colloid is located. When stained with hematoxylin-eosin, the thyroid tissue was represented by the same type of follicles, the wall of the follicles was formed by a flattened cubic epithelium located on the basement membrane. The blood supply to the thyroid gland is clearly visible. In the connective tissue between the follicles, blood vessels filled with the formed elements of the blood were determined (figure 1).



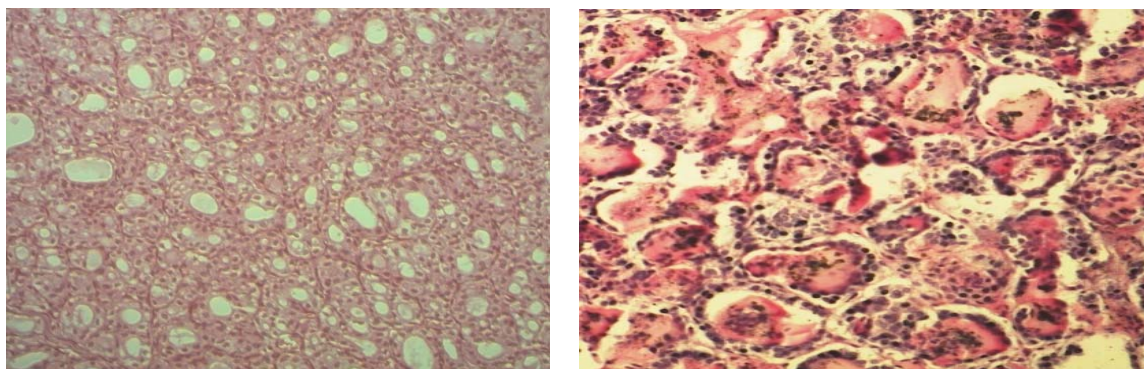
Hemocapillaries, intrafollicular colloid, thyroid structure are clearly seen. Hematoxylin and eosin stain.
Increase approx. 10×0.25 ; About. 10×20

Figure 1 – The histological structure of the thyroid gland of rats is normal

In the histological structure of the thyroid gland, the control groups are dominated by medium and large follicles, which is characterized by a normoplastic version of the structure with different sizes of follicles, which different sizes of follicles reflect the functional activity of the thyroid gland. The gland parenchyma is represented by rounded, oval or angular follicles. Follicles look like closed vesicles lined with a single-layer epithelium formed by cubic thyrocytes. The nuclei of thyroid cells have a round or oval shape.

An autopsy in all animals with hypothyroidism showed an increase in the mass of the thyroid glands by 63-34% ($p < 0.01$), i.e. the proportion of the thyroid gland in hypothyroid rats is 1.5-2 times larger than the proportion of glands in rats from the control group. In experimental hypothyroidism, the thyroid follicles were stretched and their sizes were increased, epithelial cells had a flat and elongated shape, the walls of the follicles acquire fuzzy outlines, enlarged, swollen, slightly stained. In lobes of the thyroid gland, single follicles with a small amount of colloid are found. Blood vessels, especially venous ones, are dilated, characterized by plethora and stagnation of blood.

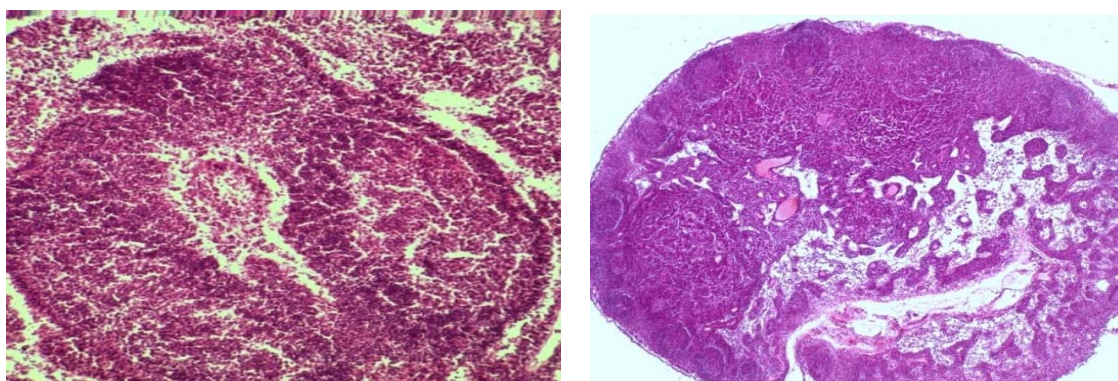
The results of the study showed that in animals with experimental hypothyroidism, destructive processes are detected. With hypothyroidism in the thyroid gland, there were significant changes in its structure and an increase in wall thickness, violation of the shape of the nuclei, desquamation of epithelial cells, which is reflected in a decrease in the diameter of the follicles, the total volume, volumes of the colloid and follicular epithelium. At the same time, swelling and rounding of the thyroid gland itself were observed. The follicles are small in size, some of them lack colloid and are filled with a clear fluid (figure 2).



Hyperplasia of the parenchyma, a change in the newly formed and deformed follicles, an increase in the thickness of the follicle wall, partial desquamation of the epithelium, abnormal shape of the nuclei, vacuolization of the cytoplasm, expansion of the interfollicular space. Stained hematoxylin and eosin. Increase Approx. 10x0,25; About. 10x20

Figure 2 – The histological structure of the thyroid gland of rats with experimental hypothyroidism

In animals, the cervical lymph nodes are normally covered with a thin, dense capsule. The subcapsular (marginal) sinus is well defined, densely filled with cells. Normally, the structure of the cervical lymph nodes is represented by a uniform development from the main structural and functional zones, there is a clear cortex-brain border in the cervical nodes, an intermediate morphotype of the lymph node is observed, in which there is a slight predominance of cortical substance over the brain substance of the lymph node, and the cortical/medullary ratio of the cervical node is 1.36 ± 0.07 (figure 3, table 1).



Paracortex is normal. Hematoxylin-eosin stain. Increase approx. 10x0.25; About. 10x20

Figure 3 – Paracortex, located between the cortical and medullary substance of the cervical lymph node in the control group of animals

Table 1 - The structure of the cervical lymph node and indices under normal and with hypothyroidism

Lymph node structures and indices	Control group	Hypothyroidism
Capsule	1,26±0,05	0,96±0,03
subcapsular sinus	0,71±0,09	0,25±0,04*
Cortical plateau	2,33±0,14	1,36±0,12
Lymphoid nodules without a germinal center(F ₂)	1,56±0,06	0,96±0,13*
Lymphoid nodules with a germinal center (Φ ₂) (F ₁)	2,43±0,13	1,45±0,39*
paracortex	5,55±0,25	3,74±0,42* ^o
Billroth's strand	7,19±0,36	6,72±0,29
Medullar sinus	2,01±0,15	4,33±0,27** ^o
The total cross-sectional area of the lymph node	22,91±1,57	19,91±1,26 ^o
Index K/M	1,36±0,07	0,72±0,01* ^o
Indes F ₁ /F ₂	1,54±0,08	1,50±0,06 ^o

Note: significantly compared with control at P <0.05 *; P <0.01 **

In the literature, such a morphotype indicates sufficient detoxification-transport and immune function of the lymph node regional for the thyroid gland [24, 25]. Their ratio often changes depending on the state of the internal environment of the body, on the influence of environmental factors, which reflects a change in the functional state of the lymph nodes. The cortical zone contains lymphoid nodules with or without a germinal center, as well as paracortex. The cortical substance contains lymphoid nodules without a germinal center (primary follicles) and lymphoid nodules with a germinal center (secondary follicles). The ratio of lymphoid nodules with a germinative center to lymphoid nodules without a germinative center is on average 1.56 ± 0.06 and indicates the predominance of lymphoid nodules with a germinative center. The deep cortex (paracortex) has an ovoid shape and occupies an area equal to $5.55 \pm 0.25\%$, on the border of the cortical and medullary substance (figure 3, fable 1). The initial area of the lymph node averages $22.91 \pm 1.57\%$. Initially, intranodular structures are developed and occupy a certain area in the general structure of the lymph node. The subcapsular sinus is quite wide and occupies an area equal to $0.71 \pm 0.09\%$. In the medullary substance, the largest part is occupied by the Billroth's strand $7.19 \pm 0.36\%$; the cerebral sinus accounts for a small part of the area, equal to $2.01 \pm 0.15\%$ (table 1).

The medullary substance of the node contains Billroth's strand and cerebral sinus, the ratio of the areas of which can also change in an alarming environment or the influence of adverse environmental factors. The indicated functional zones of the cervical lymph node are responsible for the immune and drainage-detoxification function in the body.

After the use of mercazolil, we observed a decrease in the total area of the lymph node by 13.1% compared with the control group of animals. In experiments, it was shown that at hypothyroidism, the cortical/medullary ratio decreases to 0.72 ± 0.01 , which indicates the predominance of the brain substance in the structure of the lymph node. In the brain substance of the lymph nodes after the use of mercazolil, there is a statistically significant increase in the area of the cerebral sinus by 2.15 times. An increase in the area of the cerebral sinus is associated with a decrease in the lymphoid parenchyma of the node caused by the intake of mercazolil.

The results indicate a high sensitivity not only of the bloodstream (which is consistent with the literature), but also of the lymphatic channel to a hypothyroid state. The parallelism between the progressive damage of some endocrinocytes, impaired lymphatic drainage and activation of the proliferative processes of the preserved epithelium and stroma is regarded as a compensation mechanism in the thyroid gland. The histological and equivalents of impaired hormonal synthesis of the thyroid gland, leading to its hypofunction, have been obtained. There is a certain relationship between changes in the thyroid gland and lymph node, suggesting the priority of the latter in the implementation of drainage and detoxification function in the lymphatic region.

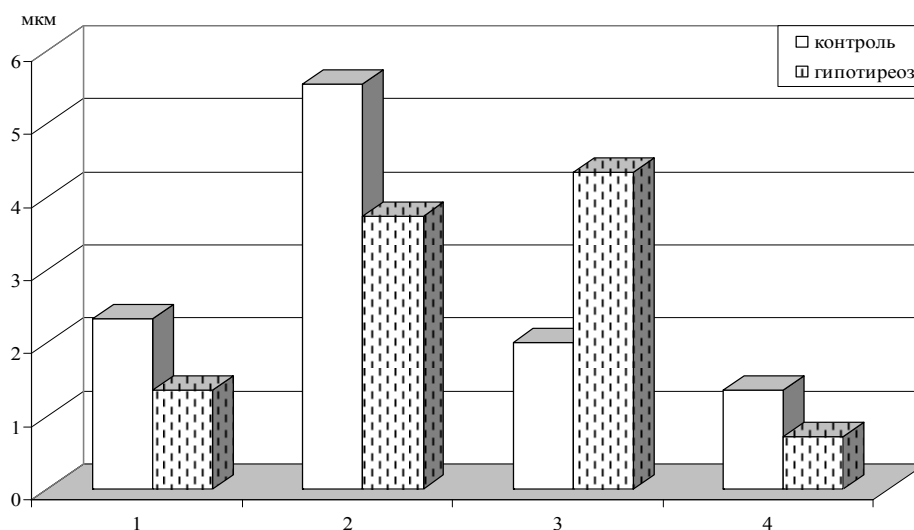
Changes in the structure of the lymph node are observed, a shift of the lymphoid nodules inward, with their placement at the border of the superficial and deep cortex, is noted. At the same time, the area of lymphoid nodules with a germinal center and without it when taking mercazolil decreases 1.6-1.67 times. Characteristic intracortical sinuses with a dense arrangement of lymphocytes are found, lymphoid nodules are oriented into the lumen of the sinus. In the cortical substance, the area of the subcapsular sinus, in which lymphoid cells are densely located, is statistically significantly reduced by 2.8 times (figure 4).

On sections of the lymph node, capsule infiltration with lymphoid elements is often observed. The value of paracortex is statistically significantly reduced by 1.4-1.48 times when taking mercazolil. The decrease in the area of the paracortical zone is relative, since it occurs due to the formation of sinuses. Blood vessels are blood-filled, this indicates an increased vascularization of the lymph node in the presence of mercazolil. Within a month of the use of mercazolil, an increase in the area of the lymph node occurs, which leads to a uniform development of the structures of the cortical and brain substances of the lymph node.

The results obtained are consistent with the results of other authors who studied the structural state of the thyroid gland and indicate a weakening of its functional activity in hypothyroidism [26].

Thus, the use of mercazolil leads to a violation of the morphofunctional state of the thyroid gland and cervical lymph node. Changes were identified especially in the peripheral zones of the thyroid lobes, which led to a decrease in the size of follicles, and in thyrocytes to a change in cellular elements, which caused a decrease in the production of thyroid hormones and impaired development of reactive and compensatory changes in the thyroid gland. The structurally functional component related to both the

thyroid gland and the lymph node is the extracellular space with vascular and non-vascular paths of microcirculation, a change in which leads to disruption of the vesicular-colloid transport in the thyroid cytoplasm and to a change in the functional state of the thyroid gland.



Designations: along the ordinate axis - the area of the main zones of the site in microns.
On the abscissa axis of the node: 1 – cortical plateau, 2 – paracortex, 3 – cerebral sinus, 4– K / M index.
Figure 4 – Change in the ratio of the structural and functional zones of the cervical lymph node in rats of the control group and at experimental hypothyroidism

There are changes in the regional lymph node, which are characterized by a change in the ratio of cortical and medullary substance, in which the proportion of structures of the cortical substance decreases, an increase in the number of macrophages in the lymphoid nodule, the medullar sinus, a decrease in the number of mature plasmocytes, in the paracortex and Billroth's strand were observed. Changes in the cortex-brain ratio with the predominance of the brain substance in the lymph node and a decrease in the proportion of structures of the cortical substance against the background of ectopic lymphoid nodules. These changes indicate manifestations of an immunosuppressive effect on the lymph node. On sections of the lymph node, capsule infiltration with lymphoid elements was often observed. The value of paracortex was statistically significantly reduced. The decrease in the area of the paracortical zone is relative, since it occurs due to the formation of sinuses. Blood vessels are blood-filled in the lymph node. There was an increase in the volume of the lymph node, which leads to a uniform development of the structures of the cortical and medulla of the lymph node.

С.Н. Әбдірешов¹, Ұ.Н. Қожаниязова¹, Г.А. Демченко¹, Ш.С. Шыныбекова², Ұ.Б. Наурызбай¹

¹ҚР БҒМ ҒК Адам және жануарлар физиологиясы институты, Алматы, Қазақстан;

²Абай атындағы Қазақ ұлттық педагогикалық университеті, Алматы, Қазақстан

ҚАЛЫПТЫ ЖӘНЕ ГИПОТИРЕОЗ КЕЗІНДЕГІ ҚАЛҚАНША БЕЗІ МЕН АЙМАҚТЫҚ ЛИМФА ТҮЙІНДЕРІНІҢ МОРФОФУНКЦИОНАЛДЫ ЕРЕКШЕЛІКТЕРІ

Аннотация. Мақалада тиреоидты жеткіліксіздік кезіндегі лимфа түйіндерінің функционалдық құрылымының арақатынасы туралы деректер келтірілген. Мерказолилді 30 күн ішінде қабылдау қалқанша безінің және мойын лимфа түйінінің морфофункционалды жағдайын бұзады. Гистологиялық, морфометриялық талдау мәліметтері бойынша қалқанша безінің мерказолилдің айлық әсеріне жоғары сезімталдылығы көрсетілген, бұл қалқанша безі мен лимфа түйіні ұлпаларының шағын ауданында синхронды морфологиялық қайта құрылу барысынан көрінеді. Өзгерістер әсіресе қалқанша безінің шеткі аймақтарында пайда болады, бұл фолликул мөлшерінің азаюына, ал тиреоциттерде жасушалық элементтердің өзгеруіне әкеледі, бұл өз

кезегінде тиреоидты гормондар өнімін азайтып, қалқанша бездегі реактивті және компенсаторлық өзгерістердің дамуына зақым келтіреді. Қалқанша бездегі және лимфа түйініндегі бір мезілде атқаратын құрылымдық функционалдық компоненттер, қалқанша безінің тиреоцит цитоплазмасында везикулярлы-коллоидты тасымалдануының бұзылуына, микроциркуляцияның тамырлы және тамырлы емес жолдары клеткадан тыс кеңістікте функционалдық жағдайының өзгеруіне байланысты анықталады.

Аймақтық лимфа түйінінде, сыртқы және мұлы заты арақатынасының өзгерісі негізінде сипатталады, онда сыртқы затының құрылымы үлесінің азайғандығы, ми синусындағы макрофагтар санының артқандығы, жетілген плазмциттер саны мен паракортекс пен жұмсақ тіннің азайғандығы байқалады. Бұл өзгерістер лимфа түйінінде иммуносупрессивті әсердің пайда болуына байланысты. Лимфа түйіні кесінділерінде жиі лимфоидты элементтермен капсуланың инфильтрациясы байқалды. Паракортекс мөлшері статистикалық түрде төмендеді. Паракортикальды аймақ аумағының азаю жағдайы салыстырмалы сипатқа ие, себебі синустардың қалыптасуы есебінен орын алады. Лимфа түйінінде қан тамырлары қанға толы. Лимфа түйінінің көлемі ұлғайған, бұл жағдай лимфа түйінінің сыртқы және мұлы зат құрылымын біркелкі дамытады.

Түйін сөздер: гипотиреоз, қан, егеуқұйрық, лимфа түйіні, қалқанша безі.

С.Н.Абдрешов¹, У.Н.Кожаниязова¹, Г.А.Демченко¹, Ш.С. Шыныбекова², У.Б.Наурызбай¹

¹Институт физиологии человека и животных КН МОН РК, Казахстан, Алматы;

²Казахский педагогический национальный университет им.Абая, Казахстан, Алматы

ОСОБЕННОСТИ МОРФОФУНКЦИОНАЛЬНОГО СОСТОЯНИЯ ЩИТОВИДНОЙ ЖЕЛЕЗЫ И РЕГИОНАРНОГО ЛИМФАТИЧЕСКОГО УЗЛА В НОРМЕ И ПРИ ГИПОТИРЕОЗЕ

Аннотация. В статье приведены данные о соотношении функциональных структур лимфатических узлов при тиреоидной недостаточности. Прием мерказолила в течение 30 дней приводил к нарушению морфофункционального состояния щитовидной железы и шейного лимфатического узла. По данным гистологического, морфометрического анализа щитовидной железы показана высокая чувствительность к месячному воздействию мерказолила, что выражается в синхронной морфологической перестройке тканевого микрорайона щитовидной железы и лимфатического узла. Изменения выявлены особенно в периферических зонах долей щитовидной железы, что приводило к уменьшению размеров фолликулов, а в тиреоцитах – к изменению клеточных элементов, что вызывало снижение продукции тиреоидных гормонов и нарушение развития реактивных и компенсаторных изменений в щитовидной железе. Структурно функциональным компонентом, относящимся одновременно к щитовидной железе и к лимфатическому узлу, является внеклеточное пространство с сосудистыми и несосудистыми путями микроциркуляции, изменение которого приводит к нарушению везикулярно-коллоидному транспорту в цитоплазме тиреоцита и к изменению функционального состояния щитовидной железы.

Наблюдаются изменения в регионарном лимфатическом узле, которые характеризуются изменением в соотношении коркового и мозгового вещества, при котором уменьшается доля структур коркового вещества, наблюдалось увеличение числа макрофагов в лимфоидном узелке, мозговом синусе, уменьшение числа зрелых плазмцитов, в паракортексе и мякотных телях. Эти изменения говорят о проявлениях иммуносупрессивного действия на лимфатический узел. На срезах лимфатического узла часто наблюдалась инфильтрация капсулы лимфоидными элементами. Величина паракортекса статистически значимо снижалась. Уменьшение площади паракортикальной зоны имеет относительный характер, так как происходит за счет формирования синусов. Кровеносные сосуды кровенаполнены в лимфатическом узле. Происходило увеличение объема лимфатического узла, что приводит к равномерному развитию структур коркового и мозгового вещества лимфатического узла.

Ключевые слова: гипотиреоз, кровь, крысы, лимфатический узел, щитовидная железа.

Information about authors:

Abdreshov Serik Nauryzbaevich, candidate's degree in Biological sciences, ass. professor Laboratory of the Lymph System Physiology, Institute of Human and Animal Physiology CS MES RK, Almaty, e-mail: SNABDRESHOV@mail.ru;

Kozhaniyazova Ulbolssin Nurgalievna, Junior Researcher Laboratory of the Lymph System Physiology, Institute of Human and Animal Physiology CS MES RK, Almaty, e-mail: y-l-b-o-ss-i-n@mail.ru;

Demchenko Georgii Anatolevich, d.m.s., Head of Lab. Laboratory of the Lymph System Physiology, Institute of Human and Animal Physiology CS MES RK, Almaty, e-mail: georgiidemchenko@mail.ru;

Shynybekov Sholpan Shanovna, Senior named teacher of the Abai Kazakh National Pedagogical University, Almaty, e-mail: sholpan_63@inbox.ru;

Nauryzbai Ulzhan Beibitovna, Senior Assistant Laboratory of the Lymph System Physiology, Institute of Human and Animal Physiology CS MES RK, Almaty, e-mail: ulzhan.n_1103@mail.ru

REFERENCES

- [1] Abdreshov S.N., Demchenko G.A., Bulekbaeva L.E., Nurmakhanova B.A., Nauryzbai U.B., Koganezawa U.N. Changes of the thyroid hormones concentration and the biochemical parameters features of lymph and blood of rat with hypothyroidism // News of the National Academy of Sciences of the Republic of Kazakhstan, Series of Biological and Medical, 2018, №6(330), P.30-36. <https://doi.org/10.32014/2018.2518-1629.14>
- [2] Kamilov F. Kh., Mamtsev A. N., Kozlov V. N., Abdullina G. M., Lobyreva O. V. Activity of antioxidant enzymes and processes of free radical oxidation in experimental hypothyroidism and correction of thyroid shifts by iodized polysaccharide complex // Kazan medical journal, 2012. Vol. 93, № 1. P. 116-119.
- [3] Mamtsev A. N., Lobyreva O. V., Kasyanov Yu. V., Kamilov F. Kh., Abdullina G. M. Activity of NAD(f)-dependent dehydrogenases in liver tissues in experimental thyroid dysfunction // Naukovi prazi: Odessa national Academy of kharchovikh Technologii. - Odessa, 2012. V.42, Vol. 2. P. 134-136.
- [4] Kashchenko S. A., Goncharova M. V. Ultramicroscopic changes in the rat thyroid gland after immunosuppression // Morphology, Vol. 7, № 3, – 2013. C. 49-53.
- [5] Abdreshov S.N. Contractile activity of mesenteric lymph nodes in toxic hepatitis // News of the National Academy of Sciences of the Republic of Kazakhstan, Series of Biological and Medical, 2007. №3 (261), C.50-54. <https://doi.org/10.32014/2018.2518-1629>
- [6] Abdreshov S.N. Influence of carbon 4-chloride on lymph flow and biochemical composition of lymph and blood plasma // The Bulletin of the National Academy of Sciences of the Republic of Kazakhstan. №3, 2005, C.81-84.
- [7] Bulekbaeva L.E., Demchenko G.A., Balkhybekova A.O., Abdreshov S.N. Contractile activity of lymph nodes in alloxan diabetes and after antioxidant correction // Astana medical journals, 2008. №1(46), P.181-183.
- [8] Demchenko G.A., Abdreshov S.N. Influence of cadmium chloride and enterosorbent on lymphodynamics and lymph composition // News of the National Academy of Sciences of the Republic of Kazakhstan, Series of Biological and Medical, 2004, №1, P.40-45. <https://doi.org/10.32014/2018.2518-1629>
- [9] Abdreshov S.N., Achmetbaeva N.A., Atanbaeva G.K., Mamataeva A.T., Nauryzbai U.B. Adrenergic innervation of the thyroid, blood and lymph vessels and lymph nodes under hypothyroidism // Bulletin of Experimental Biology and Medicine, Vol. 168, №2, P.295-299.
- [10] Borodin Yu. I. Regional lymphatic drainage and lymphodetoxification // Morphology, 2005, №40, P. 25-28.
- [11] Abdreshov S.N., Bulekbaeva L.E., Demchenko G.A. Contractile activity of the thoracic duct and lymph nodes of rats under antihypertensive influence // I. M. Sechenov Russian journal of physiology, 2011, Vol. 97, №5, P. 509-514.
- [12] Bordin Yu.I. Lymphology as integrative medical-biological science // Vestnik limfologii. 2009, №4. P. 6-9.
- [13] Abdreshov S.N., Bulekbaeva L.E., Demchenko G.A. Lympho- and Hemodynamics in Dogs with Actue Experimental Pancreatitis // Bulletin of Experimental Biology and Medicine. Vol. 159, №1, 2015, P.32-34.
- [14] Borodin Yu. I. the Lymphatic system and aging // Fundamental research. 2011, №5, P. 11-15.
- [15] Borodin Yu. I. Ecological lymphology: morphofunctional characteristics of the lymphatic system // Bulletin of the SB RAMS, 1989. N3. C. 5-11.
- [16] Borodin Yu. I. Lymph node as a marker of environmental pressure on the biosystem// Bulletin of SO RAMS-1993-N2. P. 3-10.
- [17] Borodin Yu. I., Gorchakova O. V., Gorchakov V. N. Structural reorganization of the lymph node with hypothyroidism and in conditions of early lymphotropic phytotherapies // Bulletin NSU. Series: biology, clinical medicine, 2009, Vol. 7. №2, P. 124-130.
- [18] Orlov S. B., Titova M. A., Mukhina I. A. resection of the small intestine as an experimental model of hypothyroidism // Morphology. 2002. № 2. P. 117-118.
- [19] Kozlov V.N. Thyroid transformation at modeling endemic effect in white rats in experiment // Siberian medical journal, 2006, №5, P. 27-30.
- [20] Govyrin V. A. Adaptacionno-troficheskaja funkciya sosudistyh nervov // Razvitie nauchnogo nasledija akad. L.A. Orbelli. L.: Nauka, 1982. P. 169-181.
- [21] Merkulov G. A. Course of pathohistological techniques. L.: Med., 1969, P. 79-81.
- [22] Avtandilov G. G. Medical morphometry. M., Medicine, 1990, 384 p.
- [23] Rogers L.F. Magnetic resonance images of reactive lymphadenitis. Lymphology, 2006, Vol.39, P.53-54.
- [24] Yaglova N. V. Cytophysiological features of the population of thyroid mast cells under the influence of lipopolysaccharide. Morphology statements. 2008; (3-4): 94-98.
- [25] Stepanov A. A., Kryshchov V. V. Comparative morphofunctional characteristics of the thyroid gland under dynamic and static physical loads // Morphology, 2007, Vol. 131, №1, P. 49-53.
- [26] Verheesen, R.H., Schweitzer, C.M. Iodine deficiency, more than cretinism and goiter. Med. Hypotheses. 2008; 71 (5): 645–648.

Publication Ethics and Publication Malpractice in the journals of the National Academy of Sciences of the Republic of Kazakhstan

For information on Ethics in publishing and Ethical guidelines for journal publication see <http://www.elsevier.com/publishingethics> and <http://www.elsevier.com/journal-authors/ethics>.

Submission of an article to the National Academy of Sciences of the Republic of Kazakhstan implies that the work described has not been published previously (except in the form of an abstract or as part of a published lecture or academic thesis or as an electronic preprint, see <http://www.elsevier.com/postingpolicy>), that it is not under consideration for publication elsewhere, that its publication is approved by all authors and tacitly or explicitly by the responsible authorities where the work was carried out, and that, if accepted, it will not be published elsewhere in the same form, in English or in any other language, including electronically without the written consent of the copyright-holder. In particular, translations into English of papers already published in another language are not accepted.

No other forms of scientific misconduct are allowed, such as plagiarism, falsification, fraudulent data, incorrect interpretation of other works, incorrect citations, etc. The National Academy of Sciences of the Republic of Kazakhstan follows the Code of Conduct of the Committee on Publication Ethics (COPE), and follows the COPE Flowcharts for Resolving Cases of Suspected Misconduct (http://publicationethics.org/files/u2/New_Code.pdf). To verify originality, your article may be checked by the originality detection service Cross Check <http://www.elsevier.com/editors/plagdetect>.

The authors are obliged to participate in peer review process and be ready to provide corrections, clarifications, retractions and apologies when needed. All authors of a paper should have significantly contributed to the research.

The reviewers should provide objective judgments and should point out relevant published works which are not yet cited. Reviewed articles should be treated confidentially. The reviewers will be chosen in such a way that there is no conflict of interests with respect to the research, the authors and/or the research funders.

The editors have complete responsibility and authority to reject or accept a paper, and they will only accept a paper when reasonably certain. They will preserve anonymity of reviewers and promote publication of corrections, clarifications, retractions and apologies when needed. The acceptance of a paper automatically implies the copyright transfer to the National Academy of sciences of the Republic of Kazakhstan.

The Editorial Board of the National Academy of sciences of the Republic of Kazakhstan will monitor and safeguard publishing ethics.

Правила оформления статьи для публикации в журнале смотреть на сайте:

www.nauka-nanrk.kz

ISSN 2518-1483 (Online), ISSN 2224-5227 (Print)

<http://reports-science.kz/index.php/en/archive>

Редакторы: *М. С. Ахметова, Д. С. Аленов, А. Ахметова*

Верстка на компьютере *А. М. Кульгинбаевой*

Подписано в печать 06.08.2020.

Формат 60x881/8. Бумага офсетная. Печать – ризограф.

14 п.л. Тираж 500. Заказ 4.